



CELLULITE TREATMENT USING SUBCISION AND POLYMETHYL METHACRYLATE FILLING (GOLDINCISION®): CASE REPORT

Roberto Chacur

Honório Sampaio Menezes

Danuza Dias Alves

Nívea Maria Bordin da Silva Chacur

Renata D'Oliveira Bataioli

Raíssa Nardi

ABSTRACT **Introduction:** Cellulite is a multifactorial subcutaneous connective tissue disorder that compromises the structure of adipose tissue and can manifest in varying degrees. It causes both unsightly and health changes; thus, requiring specialist treatment.

Objective: This work aims at showing the effectiveness of treatments using subcision and polymethyl methacrylate (PMMA) filling to treat and correct cellulite irregularities in grades three and four in the gluteal region.

Methodology: This is a retrospective study of patients who underwent two different techniques for the treatment of cellulite grades three and four. Four patients were subjected to treatment in the gluteal region to correct irregularities from cellulite in the most advanced grades, being used both the subcision and the PMMA filling techniques.

Report: Case report of four patients with follow-up treatment for cellulite grades three and four with subcision and polymethyl methacrylate filling.

Conclusion: Results were considered efficient due to satisfactorily correcting all cases of cellulite grades three and four.

KEYWORDS : cellulite; polymethyl methacrylate; plastic surgery; aesthetics

INTRODUCTION

Edematous fibrosclerotic panniculopathy or cellulite is commonly known as a dermatological alteration; however, there are different theories that define the concept of cellulite^{1,2}. One of the theories refers to the occurrence of edema in the connective tissue, which causes a large accumulation of water and generates cellulite^{1,3}. It may also be related to the compression of venous and lymphatic systems, which alters microcirculation and results in cellulite, mainly due to obesity^{4,5,6}. Other theory is that it may be associated with connective tissue projection^{4,6}, in women because it is perpendicular and in men because it is oblique, which explains the higher incidence of cellulite in females^{6,7,8}. The appearance of cellulite can also be influenced by collagen loss in the affected region, stress, sedentarism, obesity, heredity, hormonal contraceptives, age, sex, pregnancy, nutrition, among others^{1,2}. Cellulite can affect different regions of the body, palms, soles and scalp are the only unaffected parts⁹. The regions with the highest incidence of cellulite are the buttocks and the posterior thigh^{1,3}. This incidence is associated with the compression of adipose tissue, as well as with body posture, thus, increasing cellulite in these regions¹⁰. According to authors, adipose and skin tissues are affected in different ways, causing structural changes in the skin, microcirculation and adipocytes¹¹. Cellulite may present four varying degrees, according to authors Rao et al.⁷ and Rossi and Verganini². In grade one, it presents only histopathological changes. In grade two, cellulite is noticeable when the muscle is contracted or the skin is palpated. There is also decrease in temperature, loss of skin elasticity, and circulatory alteration. When cellulite presents nodules, is visible without tissue compression, and there are even changes in skin sensitivity, it is characterized as grade three. In grade four, the skin is wrinkled, sagging and presents large and painful lumps, as well as fibrosis. In this case cellulite is visible in any anatomical position^{2,7}. Cellulite, in addition to causing unsightly changes, can cause health problems, such as metabolic and circulatory insufficiency and pain, especially in the advanced stages of grades three and four. The increase in the formation of fat nodules results in the greatest degrees of cellulite. With this increase, the skin projection is opposed to the resistance strength of the connective support trabeculae found in grades three and four. Topical and/or oral drug treatments have not shown very satisfactory results when used for the most advanced grades of cellulite^{12,13}. Since not all

different cellulite treatments have proven effective, subcision is recommended for advanced cases¹⁴. For diagnosis and treatment, a specialist doctor is recommended. Subcision is a subcutaneous surgery technique with no incision. A special needle or scalpel is used to section the fibrous septae, thus, releasing the tension that the septae causes on the skin and stimulating the formation of collagen^{15,16}. Even though this procedure requires postoperative care, such as wearing compression clothing, cessation of physical activities, and local massages for a short time, it is performed in an outpatient setting, being minimally invasive, effective, and safe¹⁵. For the treatment of post-traumatic irregularities, such as injections, traumas, falls, and even of patients who have had breast implant removed and adhesions after inflammatory processes in the affected regions, polymethyl methacrylate (PMMA) filling and subcision are used¹⁷. PMMA, which is commonly used in plastic surgery, is a definitive synthetic microsphere polymer. Its biocompatibility and non-toxicity have been tested since 1930¹⁸. Formation of granulomas may occur due to its use; however, it does not depend on the technique used^{19,20}.

This paper aims at reporting the use of both subcision and PMMA filling treatments to treat and correct cellulite irregularities in grades three and four in the gluteal region.

CASE REPORT

This paper reports the cases of four female patients (Fig. 1 to 4) who searched cellulite treatment at the clinic. Their cellulite was classified as grades three and four and the proposed treatment was subcision followed by filling with polymethyl methacrylate. Initially, the patients were evaluated and an assessment form was filled out with complete anamnesis and previous treatments. There was also the filling of informed consent and a photographic record. The filling and subcision procedures were performed on an outpatient basis. All patients remained awake and actively participated throughout the procedure, giving their opinion on the volume and location to be infiltrated with the liquid implant.

TREATMENT

The patients were positioned in a standing position in front of a mirror for preoperative markings. In prone position, local anesthesia was

performed using 2% lidocaine with vasoconstrictor, respecting the ideal volume of lidocaine by body weight and diluted 1:1 in saline solution. After the marking and the application of anesthesia, approximately three to ten ml of 10% PMMA were infiltrated, depending on the need of each patient. The volume was well distributed in each of the regions to be treated with movements similar to the ones performed in a liposuction. This motion does not promote material accumulation, but a uniform distribution that stimulates collagen production and promotes a local filling in order to fill the empty space created with the subcision. The subcisions were performed with a needle specially created for this purpose, such instrument and technique are registered as GoldIncision®.

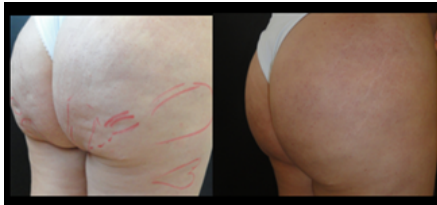


Figure 1 - Images before and after treatment using subcision (GoldIncision®) and PMMA filling.

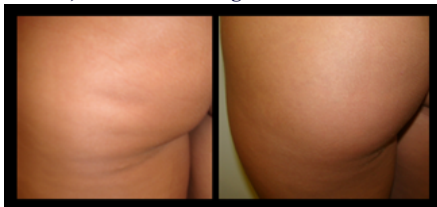

Figure 2 - Images before and after treatment using subcision (GoldIncision®) and PMMA filling.

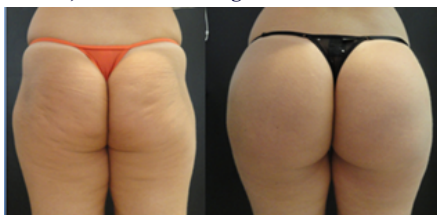

Figure 3 - Images before and after treatment using subcision (GoldIncision®) and PMMA filling.

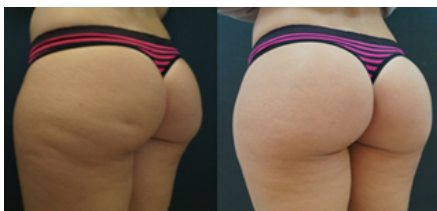

Figure 4 - Images before and after treatment using subcision (GoldIncision®) and PMMA filling.

DISCUSSION

Cellulite in advanced grades has an “orange peel” appearance (Figure 3). In affected regions, there is a hardening of the fat layer, thus, affecting the fat tissue. Cellulite provides the condition for fibrosis in adipose tissue to occur, which is associated with poor circulation and metabolic insufficiency (Figures 2 and 3). In adipose tissues with no cellulite there are empty spaces where fat moves freely²¹. In case of obesity, there are no limitations to where cellulite may appear²². Regarding the appearance of cellulite being more frequent in females, there are no studies explaining this fact^{23,24}. New techniques are emerging and others have been improved, thus, providing promising results in the treatment of cellulite. In 1997, the subcision technique was described for the treatment of cellulite grades three and four. In the present study, the subcision and the filling were complementary techniques. With the use of subcision, fibrotic septae are sectioned, freeing the skin and stimulating the formation of connective tissue that can serve as autologous and physiological fillers²⁵. Nevertheless, when using fillers, such as the PMMA used in this work, the irregularities suffered in the skin can be reduced, in addition to having the gluteal region remodeled and augmented. Moreover, PMMA stimulates neocollagenesis and is a non-absorbable product²⁶. Both techniques

have the advantage that they can be performed on an outpatient basis, are minimally invasive, and are safe and complementary, which optimizes the results obtained, as shown in this paper.

Lately, PMMA has also been used for other aesthetic and correction purposes, such as replacement of gluteal prosthesis²⁷, Poland's syndrome correction²⁸, post-liposuction lesion correction²⁹, and buttocks filling³⁰.

CONCLUSION

Significant improvement was seen after the use of both the subcision and the polymethyl methacrylate filling techniques (GoldIncision®). In these cases, the PMMA filling provided a more satisfactory result by completely correcting skin irregularities. Thus, results were demonstrated with the use of complementary, safe and minimally invasive techniques.

Acknowledgments: Augusta Ketzner Menezes for the English assistance.

REFERENCES

- Avram MM. Cellulite: a review of its physiology and treatment. *J Cosmet Laser Ther*. 2004; 6(4):181-5
- Rossi ABR, Vergnanini AL. Cellulite: a review. *J Eur Acad Dermatol. Venereol* 2000;14(4): 251-62.
- Sánchez CF, Tropper UP, Barceló R, et al. Estudios anatomopatológico e termográfico da celulite. *Rev Cosmiat Med Estet*, 1994; 1 (II):3-13.
- Rawlings AV. Cellulite and its treatment. *Int J Cosmet Sci*. 2006;28(3):175-90
- Smalls LK, Hicks M, Passeretti D, et al. Effect of weight loss on cellulite: gynoid lipodystrophy. *Plast Reconstr Surg*. 2006;118(2):510-6.
- Mirashed F, a Sharp JC, Krause V, et al. Tomanek Pilot study of dermal and subcutaneous fat structures by MRI in individuals who differ in gender, BMI, and cellulite grading. *Skin and Research Technology*, 2004; 10: 161 - 8.
- Rao J, Glod MH, Goldman MP. A two-center, double-blinded, randomized trial testing the tolerability and efficacy of a novel therapeutic agent for cellulite reduction. *J Cosmet Dermatol*. 2005;4(2):93-102.
- Querleux B, Cornillon C, Jolivet O, et al. Anatomy and physiology of subcutaneous adipose tissue by in vivo magnetic resonance imaging and spectroscopy: Relationships with sex and presence of cellulite. *Skin Res Technol*. 2002; 8(2):118-24.
- GUIRRO, E. C. O, GUIRRO, R. R. J. Fisioterapia Dermato funcional: Fundamentos, Recursos e Patologias. 3ª ed. Revisada e ampliada, 2002.
- Draeos ZD. The disease of cellulite. *J Cosmet Dermatol*. 2005; 4:221-2
- Barbanti, V. J. Aptidão física – Um convite à saúde. São Paulo, Manole, 1990.
- Elm CM, Wallander ID, Endrizzi B, et al. Efficacy of a multiple diode laser system for body contouring. *Lasers Surg Med*, 2011; 43 :114-121.
- McRae E, Boris J. Independent evaluation of low-level laser therapy at 635 nm for non-invasive body contouring of the waist, hips, and thighs. *Lasers Surg Med*, 2013; 45 : 1-7.
- Hexsel DM, R Mazzuco. Subcision: a treatment for cellulite. *Int J Dermatol*, 2000: 39(7): 539-44.
- Orentreich DS, Orentreich, N. Subcutaneous incisionless (Subcision®) surgery for the correction of depressed scars and wrinkles. *Dermatol Surg*, 1995; 21: 543-549.
- Hexsel, D, Mazzuco R. Subcision. In: Goldman M, Hexsel DM, Bacci PA, Leibashoff G. Cellulite: Pathophysiology and Treatment. Marcell-Dekker: New York, 2006. 251-262.
- Ersek R. Bioplastique at 6 years: clinical outcome studies. *Plast Reconstr Surgery*, 1997;1570-4.
- Christensen L, Breiting V, Janssen M, et al. Adverse reactions to injectable soft tissue permanent fillers. *Aesthetic Plast Surg*, 2005; 29(1):34-48.
- Vargas AF, Amorim NG, Pintanguy I. Complicações tardias dos preenchimentos permanentes. *Rev Bras Cir Plást*, 2009;24(1):71-81.
- Salles AG, Lotierzo PH, Gemperli R, et al. Complications after polymethylmethacrylate injections: report of 32 cases. *Plast Reconstr Surg*, 2008;121(5):1811-20.
- Scherwitz C, Braun-Falco O: So-called cellulite . *J Dermatol Surg Oncol*, 4: 230-234, 1978.
- Rossi ABR, Vergnanini AL.: Celulite-uma revisão . *JEADV* , 2000, 14:251-262.
- Almeida MC, Serrano CS, Roldan JR, et al. Etiologia da Celulite: uma revisão. *JEADV* , 2013;27 :273-278.
- Lotti T, Gherstetich I, Grappone C. Proteoglicanas na chamada celulite , *Br J Dermatol* , 1990; 29: 272-274.
- Garcez CE, Implantes líquidos. In: Garcez CE, Arena-de-Souza R. *Temas de Medicina Estética 2 ed* Porto Alegre: Nova Prova, 2007. P.77-113.
- Andre P. Evaluation of the safety of a non-animal stabilized hyaluronic acid (NASHA – Q-Medical, Sweden) in European countries: a retrospective study from 1997 to 2001. *J Eur Acad Dermatol Venereol* 2004;18(4):422-5.
- Chacur, R., Menezes H., Bordin, N., et al. Replacement of gluteal implants by polymethyl methacrylate filler: case report. *Case Reports in Plastic Surgery and Hand Surgery* (2019). Doi:10.1080/23320885.2018.1549946
- Chacur, R., Menezes H., Bordin, N., et al. Correction of Poland Syndrome (Chest Hypoplasia) Using Polymethylmethacrylate Implant. *Biomedical Journal and of Scientific & Technical Research* (2019). Doi: 10.26717.BJSTR.2019.14.002493
- Chacur, R., Menezes H., Bordin, N., et al. Aesthetic correction of lesion by post-liposuction corticoid infiltration using subcision, PMMA filling, and CO2 laser. *Case Reports in Plastic Surgery and Hand Surgery* (2019). Doi: 10.1080/ 23320885. 2019.1602837
- Chacur, R., Menezes H., Bordin, N. et al. Gluteal Augmentation with Polymethyl Methacrylate: A 10-year Cohort Study. *Plastic and Reconstructive Surgery* (2019). Doi: 10.1097/GOX.00000000000002193